

# Multidisciplinary Approaches to Minimally Invasive Cancer Treatment Using Colloidal Iodine: Twelve Case Reports in Digestive System

Norimasa Miura<sup>1</sup>, Takehiko Wago<sup>2</sup> and Ryusuke Fujiki<sup>3\*</sup>

\*Corresponding author: Ryusuke Fujiki

**Address:** <sup>1</sup>PEZY-Pharma, Inc., Ono bld. 3F, 3-4-18 Mejiro, Toshima-ku, Tokyo 171-0031, Japan; <sup>2</sup>YC Aoyama Clinic, YC bld.II 3F, 3-5-40 Kitaaoyama, Minato-ku, Tokyo 107-0061, Japan; <sup>3</sup>Fujiki Hospital, 225 Ooishihara, Tateyama-cho, Nakashinkawa-gun, Toyama 930-0261, Japan

**e-mail** ✉ soumu@kejinkai-f.or.jp

**Received:** 27 October 2020; **Accepted:** 02 November 2020

## ABSTRACT

**Background:** Iodine is a substance with a long history of medical application to human bodies. In addition, when targeting a tumor, the microenvironment is essential to improve the efficacy of cancer therapy. We attempted to examine the synergistic effect of colloidal iodine mainly on gastroenterological malignancies using low-dose-chemotherapy, hyperthermotherapy, and/or hyperbaric oxygen therapy.

**Materials and Methods:** Colloidal iodine was administered to 12 patients with unresectable in stage IV have an outcome that is treated with palliative medicine. who had already been diagnosed with an incurable, intractable advanced neoplasm, including pancreatic cancer, gastric cancer, esophageal cancer, cholangiocarcinoma, colon cancer, and end-stage rectal cancer. The route of administration was oral for 5 patients, intravenous for 7 patients, and topical for 2 patients. The effect was estimated using a change of tumor markers or/and the findings of endoscopy or computed tomography.

**Results:** By each modality to evaluate the effect, the addition of iodine successfully reduced tumor size and inhibited the progression of complications in all cases, compared with cases in previous studies treated without iodine. We also confirmed that intravenous infusion was a safe route of administration without adverse effects.

**Conclusions:** In this pilot study, twenty patients with advanced cancer who received treatment with colloidal iodine in nanoparticle status successfully inhibited tumor progression and improved ADL without adverse effects. As a multidisciplinary approach for both the cancer itself and its microenvironment, the complementary use of colloidal iodine may increase the rate of improvement of cancer via a biomodulating mechanism. This formulations may be useful as one of the multidisciplinary therapeutic modalities and we expect outcomes from the further phase of clinical trials.

**Keywords:** Colloidal Iodine, Cancer, Biomodulation, Multidisciplinary Therapy, Tumor Microenvironment

## Introduction

Cancer is the leading cause of death. As the human population ages, it is speculated that the mortality rate from cancer will increase (Weir *et al.*, 2015). Although anticancer drugs and molecularly targeted drugs, which directly attack cancer cells, are effective in cancer treatment, there are still limits to their effectiveness. In addition, many new therapeutic drugs such as immune checkpoint inhibitors are being developed (Hegde and Chen, 2020), but they are

limited in the number of facilities where they can be administered, are expensive, have a narrow range of indications, and have adverse effects that physicians need to be aware of and manage (Baraibar *et al.*, 2019). Furthermore, although advanced technologies such as cancer genome diagnosis have been developed, genomic cancer care is available only in a limited number of cancer centers (Cheng and Solit, 2018), and it will be some time before the general population can fully benefit from it. For patients with unresectable, intractable, and chemotherapy-resistant cancers who cannot be treated by cutting-edge medicine, physicians involved in hands-on care, including end-of-life care, are providing additional medical care, such as palliative care and are still searching for new, less invasive treatment strategies to increase therapeutic effect and response rates (Miura *et al.*, 2019).

Because cancer comprises not just the cancer cells alone, to improve the response rate and treatment efficiency, it is important to regard cancer as organic aggregates of “cancer cells” and “all of the interstitial components (fibroblasts, vascular cells, various inflammatory cells, collagen found between cells, and physiological substances such as growth factors, cytokines, and chemokines) that make up a malignant tumor” (Locy *et al.*, 2018).

The remarkable difference between biological and experimental cancers that clinicians face is in the tumor microenvironment (TME). Therefore, practicing medical doctors must take this fact into consideration when treating them (Shimizu *et al.*, 2018). The importance of TME has drawn more attention recently because a treatment that targets the malignant TME induces less therapy-resistance and adverse effects.

Based on this treatment strategy, we conducted a clinical study to evaluate the effectiveness of a biomodulating cancer therapy using colloidal iodine as well as low dose chemotherapy (Bontempo *et al.*, 2017), hyperthermotherapy (Multhoff *et al.*, 2016; Evans *et al.*, 2015), and hyperbaric oxygen (HBO) therapy (Moen and Stuhr, 2012; Stępień *et al.*, 2016). Clinical trial for stage II breast cancer (ClinicalTrials.gov: #NCT03688958; <https://clinicaltrials.gov/>) was completed with very positive results. This formulation including colloidal iodine was approved for clinics only in Sri Lanka and is currently under review for FDA approval. We attempted to confirm the usefulness of concomitant therapy with low dose chemotherapy/hyperthermotherapy/HBO therapy using colloidal iodine in this pilot study (Ohguri *et al.*, 2009; Bosco *et al.*, 2013).

## Methods

This trial included 12 patients with unresectable advanced cancer who had already been diagnosed with incurable. The list of patients enrolled in this study is shown in **Table 1**.

Colloidal iodine (JCI MN Colloidal Iodine®) was either provided or purchased for clinical use by the JCI Center (JCIC; Nihonbashi, Tokyo, Japan). The formulations for oral or

intravenous injection contained colloidal iodine (12.2 mg/ml) in a water solution. The formulation for direct topical use by endoscopy were was the same as that for oral administration. The oral ingestion dose was 160 mL/day for 30 days or longer. The intravenous infusion dose was 200 mL/dose, once daily for 10 days or more, according to the information provided by the manufacture.

**Table 1:** Clinical characteristics and treatment of the patient

Case	Age	Gender	Malignant disease	Therapy	JCI MN IODINE
1	52	M	unresectable rectal cancer with lung metastasis	XELOX / hyperthermia / HBO	i.v. once/day (10D)
2	81	F	unresectable gastric cancer	TS-1 80mg/day / hyperthermia / HBO	p.o. twice/day (10D)
3	95	M	unresectable gastric cancer	nab-paclitaxel 120mg/day / hyperthermia / HBO	i.v. twice/day (10D) + directly
4	70	M	unresectable scirrhous gastric cancer with liver metastasis	TS-1 80mg/day / hyperthermia / HBO	p.o. twice/day
5	79	F	unresectable gastric cancer	nab-paclitaxel 120mg/day (1d) / hyperthermia / HBO (6d)	p.o. twice/day (10D)
6	83	M	unresectable esophageal cancer	nab-paclitaxel 120mg/day + CBDCA 150mg (twice/6 wks.) / hyperthermia	i.v. once/day (10D)
7	75	F	unresectable pancreatic cancer	nab-paclitaxel 120mg/day + CBDCA 150mg (twice/6 wks.) / hyperthermia	i.v. once/day (10D)
8	64	M	intrahepatic cholangiocarcinoma	nab-paclitaxel 120mg/day + oxaliplatin 150mg (twice/6 wks.) / hyperthermia	p.o. twice/day (10D) + 0.4x p.o. once/day (30D)
9	72	M	gastric cancer with liver metastasis	nab-paclitaxel 120mg/day + ramucirumab / hyperthermia / HBO	i.v. twice/day (10D)
10	62	M	recurrence of rectal cancer after surgical treatment	XELOX + bevacizumab (2 cool) / hyperthermia / HBO	i.v. twice/day (14D)
11	82	F	recurrence of transverse colon cancer after surgical treatment	XELOX + bevacizumab / capecitabine / hyperthermia / HBO /	p.o. twice/day (10D) + topically
12	61	M	scirrhous gastric cancer with ascites and peritoneal dissemination	nab-paclitaxel 120mg/day + ramucirumab / hyperthermia / HBO	p.o. twice/day (10D)

M: male, F: female, N/A: not applicable, hyperthermia: hyperthermotherapy, D: days, p.o.: per os, i.v.: intraven

In these cases, we investigated whether colloidal iodine manufactured by JCIC could improve the therapeutic effect on cancer by regulating the biomodulation in the cancer environment. In detail, we used JCI MN colloidal iodine along with the 3 modalities of low dose chemotherapy, hyperthermotherapy, and HBO therapy. Colloidal iodine was administered orally, directly, or intravenously depending on the condition of the patient. The efficacy was assessed by blood tests, computed tomography (CT) or endoscopic after one or two months. Multidisciplinary treatment mainly for gastrointestinal malignancies has been used in Fujiki Hospital for a wide variety of cancers, including pancreatic cancer, gastric cancer, esophageal cancer, cholangiocarcinoma, rectal cancer, and end-stage colon cancer (Cheng *et al.*, 2019). The number of patients was 1, 6, 1, 1, 2, and 1, respectively. All patients with advanced cancer in terminal status were pre-registered and enrolled in from 2015 to 2018

and considered to have satisfied the inclusion criteria. All patients approved this project after informed consent. The registration number in our hospital is #FH201501.

Hyperthermotherapy was induced in the tumor tissue by elevating the temperature to 42–50°C for 0.5–1 h using a Thermotron RF-8 GR edition (Vinita Co., Ltd., Osaka, Japan) (Multhoff *et al.*, 2016).

Hyperbaric oxygen therapy delivered 100% oxygen to the patient's pulmonary system using a Model 3300HJ (Hokkaido Air Water Inc., Sapporo, Japan) (Stępień *et al.*, 2016). The patients breathed oxygen at levels far greater than 21%, which is found at a normal level atmosphere. Low dose chemotherapy was chosen to minimize the adverse effects and the pain of patients. XELOX (capecitabine/oxaliplatin), TS-1 (tegafur/gimeracil/oteracil potassium), nab-paclitaxel, CBDCA (carboplatin), oxaliplatin, capecitabine, ramucirumab, or/and bevacizumab was chosen in consideration of the clinical stage of disease, anticancer drug use history, and tolerance in the elderly. This study was submitted the proper protocol to and approved by the respective patient and family because the safety of these modalities has been clinically confirmed and all patients were in dangerously ill condition.

## Results

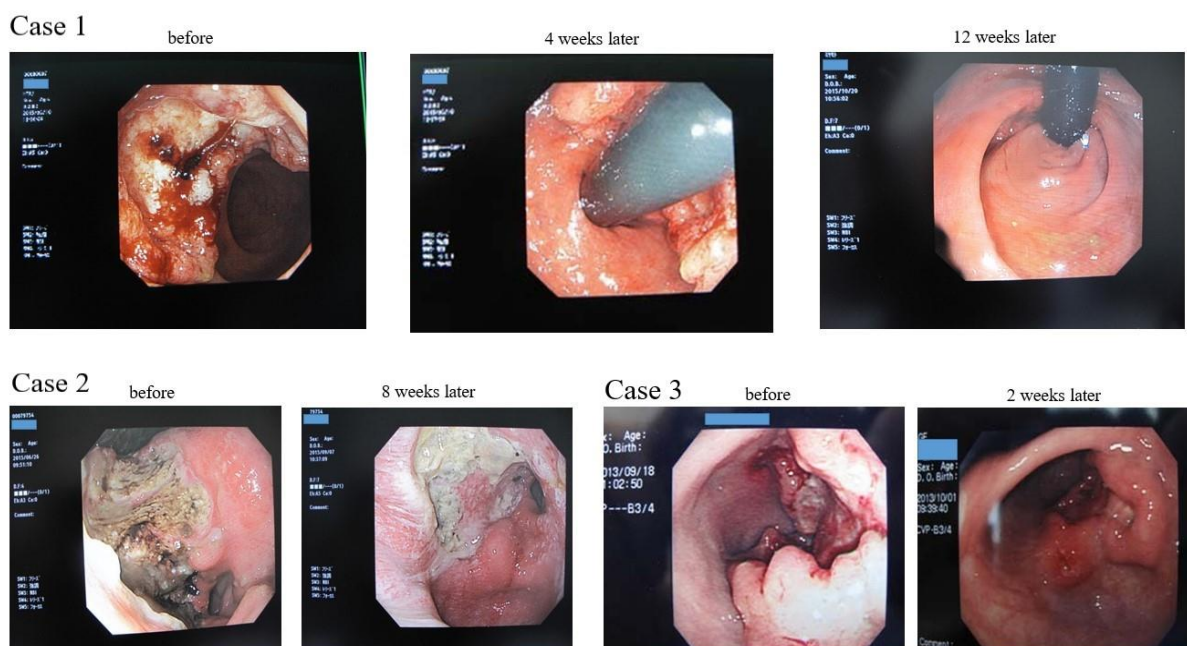
The clinical course in respective cases is summarized in **Table 2**. Briefly, in all cases, an extension of the non-proliferation period, reduction of tumor size, and improvement of physical conditions and ADL (activities of daily living) could be seen. The direct topical effect of colloidal iodine infusion therapy by washing the mucosal lesions of tumor was found to increase the response rate and therapeutic effect of low-dose chemotherapy, hyperthermotherapy, and hyperbaric oxygen therapy. Colloidal iodine was safe to administer and had no adverse effects. In the case of bleeding, a hemostatic effect by washing the bleeding area was confirmed (cases 1–3) (**Fig. 1**). An improvement of mucosal lesions of scirrhous gastric carcinoma was observed (case 4) (**Fig. 2**). Biomarkers or tumor markers showed a remarkable reduction or improvement (cases 6, 7, and 12) during this collective therapy. Endoscopic findings (**Fig. 1-2**) and CT (**Fig. 3-4**) showed the suppression of tumor progression. Stenosis by cancer progression could not be found for gastroenterological and hepatobiliary diseases (cases 1–12). Intravenous infusion as well as oral administration was effective for gastric cancer, esophageal cancer, pancreatic cancer, cholangiocarcinoma, and intractable cancer with liver metastasis, (cases 1, 3, 6, 7, and 9). These formulations had a reduction effect on pancreatic cancer in stage 4 and diffuse cholangiocarcinoma within 8 weeks (**Fig. 3**). Tumor lysis syndrome was observed in case 9. The tumor with a KRAS mutation initially enlarged in size before shrinking during the treatment in case 10, and a prominent reduction of tumor size and a surprisingly improved fistula generated by cancer progression was confirmed by topical administration in case 11 within 4 weeks (**Fig. 4**). In case 12, with peritoneal dissemination and

intractable ascites, replacement therapy of ascites (less than pH 7.3) with colloidal iodine (pH 8.5) induced no recurrence of ascites (Fig. 4). No adverse effects such as fever, skin rash, lymphadenopathy, or pain at the lesion site were observed in any case.

**Table 2:** The clinical course of the patient

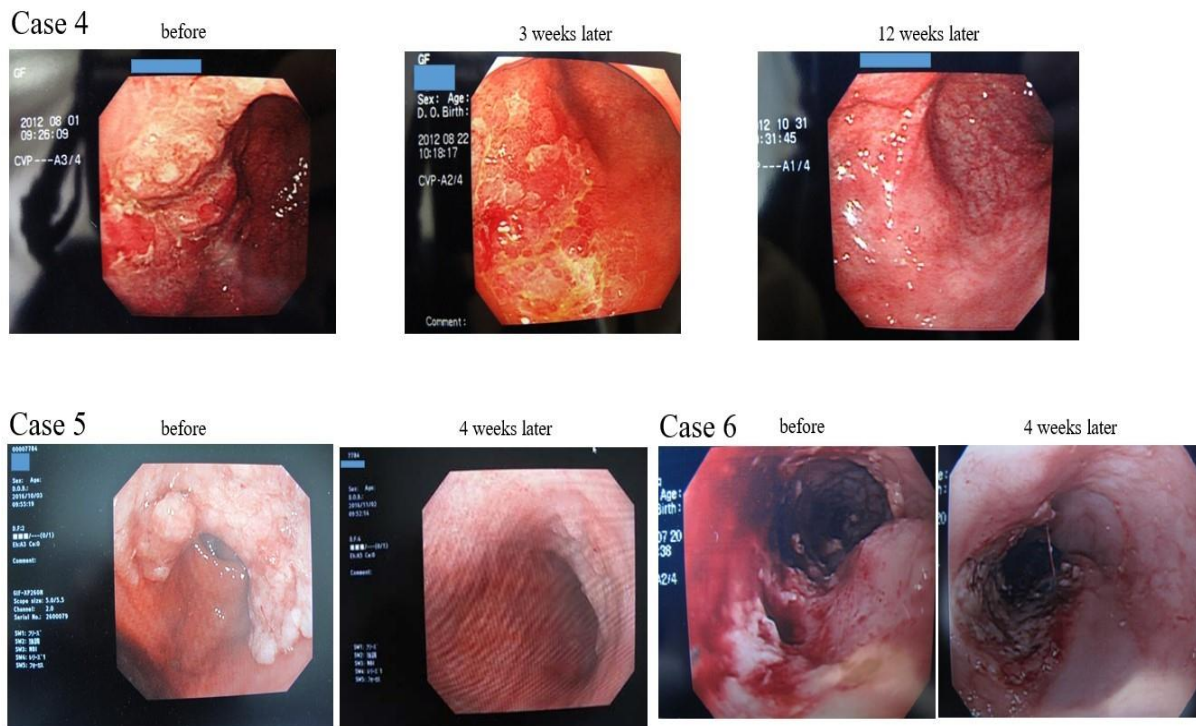
Case	Clinical course of each case
1	Giant tumor lesions with hemorrhage shrink approximately 50% after 1 month of treatment and only a few lesions after 3 months. Melena was no longer evident. Intra-abdominal lymph node metastases showed improvement, although there was no increase in lung and spine metastases.
2	Significant reduction of tumor lesions and hemostatic effect were observed. Oral intake was also available from the third week after treatment.
3	The concomitant use of colloidal iodine infusion therapy resulted in significant reduction of the tumor lesion and hemostasis in just 2 weeks.
4	One month later, the unevenness of the stomach lining disappeared, and three months later, the mucosal lesions almost disappeared. Liver metastases were unchanged.
5	Gastric endoscopy showed marked topical improvement of the lesion.
6	The reduction in esophageal tumor and improvement in stenosis status and tumor markers were observed, leading to the improvement in his food intake status
7	CT images and tumor marker CA19-9 showed a significant reduction in tumor size and a reduction from 2350 to 148, respectively.
8	Four weeks after treatment, a remarkable improvement in the CT images was observed. There were no adverse effects associated with the treatment.
9	Approximately one month later, a significant reduction of the liver metastatic lesion was observed, resulting in the concomitant tumor collapse syndrome.
10	A cessation of enlargement and reduction of the intrapelvic tumor were observed.
11	About one month after colloidal iodine was injected into the fistula in the peritoneum and abdominal wall and washed repeatedly, the abdominal wall fistula was closed and the tumor volume was markedly reduced to approximately 40%.
12	Approximately one month after treatment, she could walk on her own, take orally and was discharged from the hospital. After the replacement of ascites with 1500 ml of colloidal iodine solution, no ascites effusion was observed.

5



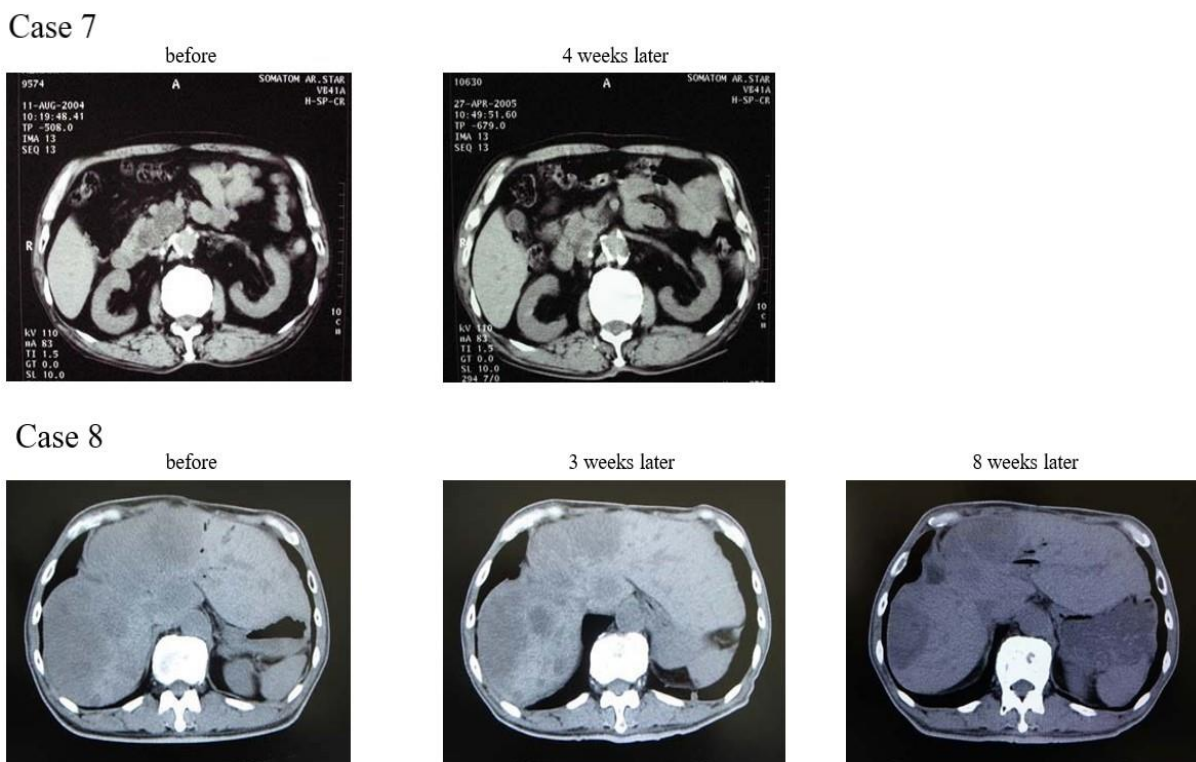
**Figure 1:** Endoscopic images showing the clinical course for case 1 to case 3. In case 1, the progressive semicircular rectal cancer with mucosal oozing gradually improved at 12 weeks after intravenous administration. In case 2, the advanced gastric cancer with blood clotting, an ulcerated surface, and a white moss improved from a continuous to non-continuous lesion in 8 weeks following the oral and daily administration. In case 3, the Borrmann type III gastric cancer with oozing shrank in size, and the surrounding mucosa appeared to be converted to a normal mucosa



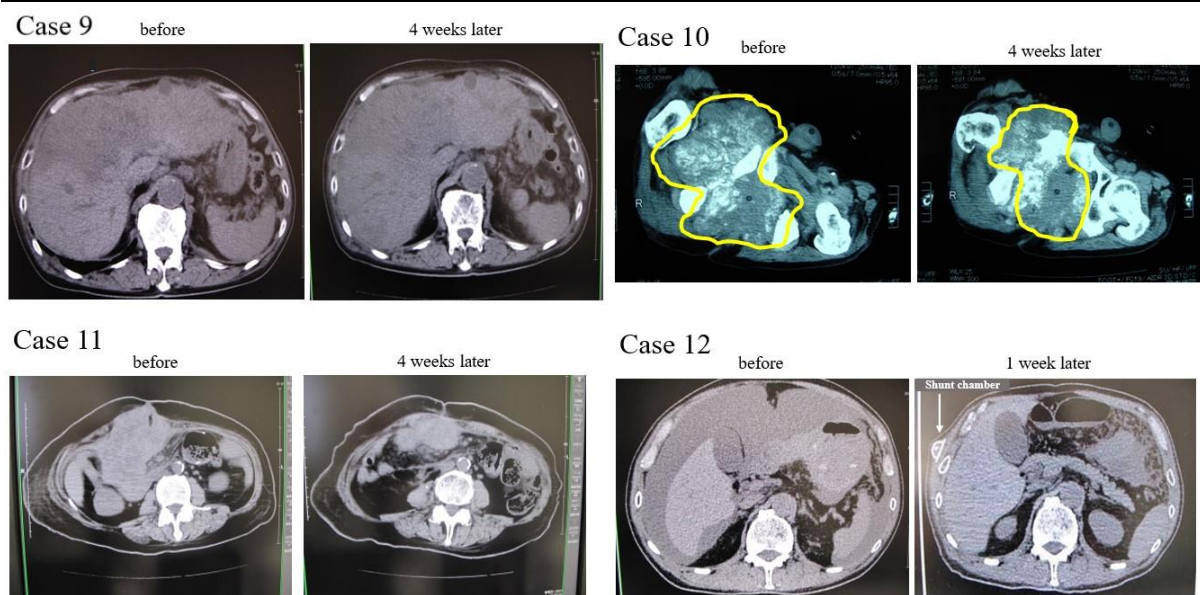


**Figure 2:** Endoscopic images showing the clinical course for case 4 to case 6. In case 4, the scirrhus gastric carcinoma at the anterior wall of the lower body of the stomach gradually changed to a normal mucosa at 12 weeks but only by oral intake of iodine. In case 5, the antral carcinoma showed a gradual change at 4 weeks. In case 6, the advanced esophageal carcinoma at the middle thoracic esophagus (Mt) with oozing and ulceration improved from a cancer-infiltrating mucosa to a mucosa without unevenness, but faintly with oozing and ulceration

6



**Figure 3:** CT images showing the clinical course of case 7 and case 8. In case 7, the mass of tumor in the uncus of the pancreas in stage 4 shrank more than 50% at 4 weeks after intravenous administration of iodine. In case 8, the occupied area of the unresectable cholangiocarcinoma reduced in size at 8 weeks by oral intake



**Figure 4:** CT images showing the clinical course for case 9 to case 12. In case 9, the improvement of rectal cancer with liver metastasis was confirmed at 4 weeks after intravenous infusion. In case 10, the reduction of intrapelvic mass was observed at 4 weeks. In case 11, the intraperitoneal mass with a fistula on the abdominal wall was effectively treated with the topical and oral administration of iodine, resulting in shrinkage of the tumor mass. In case 12, severe ascites with the progression of gastric cancer disappeared a week later by the replacement of ascites with an iodine preparation

## Discussions

Iodine is an element of the halogen group with atomic number 53 and is one of the essential minerals of thyroid hormones in humans (Bernet, 2019). It is particularly abundant in seaweed, and we get it from our diet into our bodies. Approximately 30% of the world's population is said to be iodine deficient, and iodine deficiency can cause mental developmental delays, hypothyroidism, cretinism, and growth and developmental abnormalities (Benoist *et al.*, 2004; Verheesen and Schweitzer, 2008; Shelanski and Shelanski, 1956; Galofré *et al.*, 1994a).

Iodine as a drug, such as an iodine tincture and povidone iodine, is familiar in our daily lives as a disinfectant for the skin and throat (Shelanski and Shelanski, 1956), and its sterilizing effect on viruses is particularly remarkable (Bianco *et al.*, 2002). However, because iodine itself is highly toxic, these products can be used to disinfect and sterilize the surface of the skin and mucous membranes, but cannot be taken into the body (Galofré *et al.*, 1994a; Galofré *et al.*, 1994b).

Minimally invasive combined therapy with colloidal iodine (JCI MN Iodine®) is attracting worldwide attention as a future cancer treatment method (Yokoyama, 2018). This formulation adds iodine ions to the blood, which are taken up by the thyroid gland to become thyroid hormones (Dentice *et al.*, 2013). Iodine is then released as a protein-binding thyroid hormone and is supplied to the whole body (Hays and Solomon, 1965; Nicola *et al.*, 2009).

Although the absorption rate of iodine is dramatically higher due to colloidization (Schubert and Chanana, 2019), excess iodine (Galofré *et al.*, 1994a; Leung and Braverman, 2014), which is not involved in hormone synthesis, is rapidly excreted as iodine ions. Therefore, it does not continue to accumulate in the body like common drugs, has no tolerance, is highly safe, and minimizes the possibility of iodine-induced toxicity. However, physicians should be careful at present when administrating to patients with hyperthyroidism, Hashimoto disease, or viral infections except for the cold virus.

Direct topical administration is a useful method of administration for the cancer environment (Gulaboglu *et al.*, 2005) and contributes to the shrinking effect on the tumor itself (Aceves *et al.*, 2013). These are unique formulations with a nanoparticle coating that allows iodine to be safely taken into the body without iodine allergy. The formulations can be applied to examine the pharmacological effects on cancer or intractable diseases so that we can use them safely in clinical trials (Venturi *et al.*, 1993). In contrast, colloidal iodine in practical cancer therapy is absorbed into the blood as an iodine ion, and acts, as its main mode of action, as iodine contained in protein-binding thyroid hormones. Iodine acts directly on peripheral blood lymphocytes to regulate T cell proliferation and differentiation, cytokine production, and IgE production (Spitzweg *et al.*, 2000) and acts on fibroblasts to inhibit IL4 and TNF $\alpha$  activation and protect organs from tissue damage (Iwata *et al.*, 2014). Also, by inhibiting the degradation of cancer inhibitory genes by cancer tumor proteins, G2-M arrest in the cell cycle is promoted along with tumor suppressor gene-dependent apoptosis, which potentiates the effects of chemotherapy (Arroyo-Helguera *et al.*, 2008). We presume that colloidal iodine acts by binding to tumor suppressor genes via a molecular chaperone mechanism, resulting in stabilization of the complex and enhancing other anticancer therapies (Arvan *et al.*, 1997). Iodine removes the activated oxygen created by mitochondria to enhance cell regeneration (Chaiyabutr and Jakobsen, 1978). Furthermore, it forms a conjugate with inflammatory cytokines (Spitzweg *et al.*, 2000) and tumor proteins that are fragmented by chemotherapy, inactivating the cells and proteins and attenuating the multi-drug resistance to chemotherapy (Supawat *et al.*, 2019).

Iodine-125 low-dose-rate (LDR) brachytherapy for prostate cancer has been demonstrated to induce effective immune responses in patients. The gradual and bimodal increase of activated T cells (CD3+, CD4+, and CD8+) may contribute to the maintenance of remission and reduction of relapse rates. Iodine has strong intermolecular aggregation properties due to van der Waals forces, is made into “iodine + water molecule aggregates”, and functions as an intracellular antioxidant (Rosenholm *et al.*, 2008). Free iodine (I<sub>2</sub>) oxidizes water to become hypoiodine and hydrogen iodide and efficiently scavenges intracellular hydroxyl radicals. It is particularly effective in eliminating mitochondria-derived reactive oxygen species (ROS) (Lin *et al.*, 2019). This action restores mitochondrial function, followed



by changing the anaerobic environment of cancer cells to an aerobic one and allowing the cells to be reset.

Hyperthermotherapy has anticancer effects because the formation of an HSP-complex, which activates oncogenes, is suppressed. The formulations with intermolecular forces have a high affinity for proteins such as HSP and oncogenes, leading to the inactivation of oncogenes, similar to the process of hyperthermia (Mahmood *et al.*, 2018). Furthermore, molecular motions in a colloidal dispersion system become more reactive as temperature rises, and the iodine ion can easily penetrate into cancer cells (Kogai *et al.*, 2000; Klotz and Benz, 1993), followed by the inhibition of cancer growth. This suggests the possibility of iodine as a sensitizing agent to increase the effects of thermal therapy.

In HBO therapy, arterial oxygen concentrations increase to 6-fold those of ordinary conditions. This allows induction of the cancer's TME from an anaerobic to an aerobic environment. This decreases the genetic diversity of cancers induced by low oxygen states. Recent reports have maintained that the main target of carcinogenesis may be in DNA but in mitochondria of cytoplasm (Watanabe, 2015; Zhou *et al.*, 2000). Iodine also enhances cell regeneration by activating the cell mitochondria damaged by cancer tissue, colon tissue, cerebral infarction, or myocardial infarction to assist in recovery from these conditions (Iwata *et al.*, 2014; Supawat *et al.*, 2019; Aranda *et al.*, 2013). In synergy with HBO therapy, it turns cellular anaerobic metabolism of cancer cells into aerobic metabolism, inhibiting the proliferation of cancer.

As a direct effect of colloidal iodine, we focused on the effect of replacement therapy of ascites with an alkaline formulation. This technique decreases the number of cancer-associated fibroblasts (CAF) (Shimoda *et al.*, 2010; Moreno-Vega *et al.*, 2019), which are the leading instigator in creating an intraperitoneal inflammatory environment, and helps reduce tumor-facilitating exosome miRNA and inflammatory cytokine production (Spitzweg *et al.*, 2000), thus improving the TME. We experienced cases sensitive to the tissue environment with effectiveness on refractory decubitus, skin ulcers, and skin fistulas for just a short time. In the current clinical trial, these formulations not only inhibited the exacerbation of malignant diseases but also reduced tumor mass, although reports have suggested that thyroid hormones promote the growth of colon cancer (Lee *et al.*, 2018; Catalano *et al.*, 2016).

Thus, iodine suppresses inflammation (Beukelman *et al.*, 2008) and improves the microenvironment of cancer (Bigoni-Ordóñez *et al.*, 2018). By improving tissue metabolism by restoring mitochondrial function (Yu *et al.*, 2018), it exerts anti-cancer effects through improved sugar metabolism and its anti-inflammatory and anti-allergy properties (Nava-Villalba *et al.*, 2015). Iodine also has bactericidal and anti-viral effects. It is well-known that 0.5% iodine as a disinfectant agent is most effective on viruses (influenza: H<sub>3</sub>N<sub>2</sub>, H<sub>3</sub>N<sub>2</sub>, H<sub>1</sub>N<sub>1</sub>;

coronavirus, RS virus, adenovirus) compared with other antiviral agents and reduces them to below the detection limit after 15 s (Shelanski and Shelanski, 1956). The new type of coronavirus (COVID-19), which has caused a stir in the world, is an envelope virus with a single positive-strand RNA as its viral genome (Kaushal *et al.*, 2020), and, like the SARS coronavirus, is transmitted to human cells through the ACE2 receptor. The colloidal iodine agent has a high affinity for proteins even for viral proteins. The colloidal form of the drug has various uses, not only for cancer treatment, but also for improving tissue absorption, suggesting that iodine has potential as a counter-COVID-19 agent.

Currently, colloidal iodine is administered as an intravenous drip solution, an oral solution, or an inhalation solution (Okamoto *et al.*, 2018). In addition, eye and nasal drops of iodine have a high possibility of preventing viral infections (Heimbuch *et al.*, 2015). For patients with mild illnesses, prescription of oral solutions at home or inhalation solutions with a portable nebulizer can reduce the burden on the medical scene without even requiring a hospital visit.

Colloidal iodine is a novel biomodulating therapy (Bilal *et al.*, 2017) that can support the effects of conventional anti-drugs or checkpoint inhibitors with a supplemental mechanism of action. Biogenetical modulation (BGM) regulates the formation of the gene-cancer protein complex, inhibits activation of oncogenes, and prevents decreased functioning of the tumor suppressor genes (Furth, 2012). BGM, thus, allows a marked improvement of response rates and therapeutic effect when used concomitantly with hyperthermotherapy and HBO therapy. Because colloidal iodine has a biochemical modulation (BCM) effect on chemotherapy, its use may serve to minimize or overcome the adverse effects of chemotherapy. Biomodulation (BM) effect is the overall effect comprising BGM, BCM, and biological modulation. We speculated that this BM effect is the main mechanism of action of colloidal iodine agents. Colloidal iodine with the stability of a biocompatible nanoparticle coating has a BM effect and contributes to improving the effectiveness of cancer treatment. Also, we expect that iodine will improve the sensitivity of molecular targeting chemotherapy via its action on the TME (Bhatt *et al.*, 2017), because this therapy makes the subsequent molecular-targeting therapies possible by improving physical status of patients.

## Conclusions

For the most effective strategy using this formulation, we should determine the duration and optimal dose of treatment to target or modulate the TME. Our findings will have a strong impact on future cancer treatment, although a multidisciplinary cancer treatment will be needed because the molecules that play a central role in the TME vary for different organs. This trial suggests the usefulness of colloidal iodine in the early stages of cancer in further clinical trials of this preparation.

## **Abbreviations**

HBO: Hyperbaric Oxygen; BM: Biomodulation; CT: Computed Tomography Scan; XELOX Capecitabine/Oxaliplatin; TS-1: Tegafur/Gimeracil/Oteracil Potassium; CBDCA Carboplatin; ADL: Activities Of Daily Living; COVID-19: the new type of coronavirus; SARS: Severe Acute Respiratory Syndrome; HSP: Heat Shock Protein

## **Acknowledgments**

We all deeply thank for all doctors and paramedical stuffs working at Fujiki Hospital.

## **Declarations**

### *Ethical approval and Consent to participate*

All patients approved this project after informed consent.

## **Data Availability**

The authors declare that all other data supporting the findings of this study are available within the article.

## **Authors Contributions**

The author(s) have made the following declarations regarding their contributions: **RF** conceived and designed the experiments. **TW** and **NM** analyzed the data and wrote this manuscript. **NM** and **RF** approved the final manuscript. All authors read and approved the final manuscript.

11

## **Funding Support**

N/A

## **Availability of Data and Materials**

The datasets generated for this study are available from the corresponding author on reasonable request.

## **Consent for Publication**

Not applicable.

## **Competing Interests**

All authors are aware of the consent and agree with the submission. The authors declare no conflict of interest or competing interests.

## References

Aceves C, Anguiano B, Delgado G. The extrathyronine actions of iodine as antioxidant, apoptotic, and differentiation factor in various tissues. *Thyroid* 2013; 23: 938–946.

Aranda N, Sosa S, Delgado G, Aceves C, Anguiano B. Uptake and antitumoral effects of iodine and 6-iodolactone in differentiated and undifferentiated human prostate cancer cell lines. *Prostate* 2013; 73: 31–41.

Arroyo-Helguera O, Rojas E, Delgado G, Aceves C. Signaling Pathways Involved in the Antiproliferative Effect of Molecular Iodine in Normal and Tumoral Breast Cells: Evidence That 6-iodolactone Mediates Apoptotic Effects. *Endocr Relat Cancer* 2008; 15, 1003–1011.

Arvan P, Kim PS, Kuliawat R, Prabakaran D, Muresan Z, Yoo SE, Abu Hossain S. Intracellular protein transport to the thyrocyte plasma membrane: potential implications for thyroid physiology. *Thyroid* 1997; 7: 89–105.

Baraibar I, Melero I, Ponz-Sarvisé M, Castanon E. Safety and Tolerability of Immune Checkpoint Inhibitors (PD-1 and PD-L1) in Cancer. *Drug Saf* 2019; 42: 281–294.

Benoist BD, Andersson M, Egli I, Takkouche B, Allen H. Iodine Status Worldwide. Geneva: *World Health Organization* 2004.

Bernet VJ. Thyroid hormone misuse and abuse. *Endocrine* 2019; 66: 79–86.

Beukelman CJ, van den Berg AJ, Hoekstra MJ, Uhl R, Reimer K, Mueller S. Anti-inflammatory properties of a liposomal hydrogel with povidone-iodine (Repithel) for wound healing in vitro. *Burns* 2008; 34: 845–855.

Bhatt AP, Redinbo MR, Bultman SJ. The Role of the Microbiome in Cancer Development and Therapy. *CA Cancer J Clin* 2017; 67: 326–344.

Bianco AC, Salvatore D, Gereben B, Berry MJ, Larsen PR. Biochemistry, cellular and molecular biology, and physiological roles of the iodothyronine selenodeiodinases. *Endocr Rev* 2002; 23: 38–89.

Bigoni-Ordóñez GD, Ortiz-Sánchez E, Rosendo-Chalma P, Valencia-González HA, Aceves C, García-Carrancá A. Molecular iodine inhibits the expression of stemness markers on cancer stem-like cells of established cell lines derived from cervical cancer. *BMC Cancer* 2018; 26; 18: 928.

Bilal MY, Dambaeva S, Kwak-Kim J, Gilman-Sachs A, Beaman KD. A Role for Iodide and Thyroglobulin in Modulating the Function of Human Immune Cells. *Front Immunol* 2017; 15: 1573.

Bontempo A, Ugalde-Villanueva B, Delgado-González E, Rodríguez ÁL, Aceves C. Molecular iodine impairs chemoresistance mechanisms, enhances doxorubicin retention and induces downregulation of the CD44+/CD24+ and E-cadherin+/vimentin+ subpopulations in MCF-7 cells resistant to low doses of doxorubicin. *Oncol Rep* 2017; 38: 2867–2876.

Bosco G, Guizzon L, Yang Z, Camporesi E, Casarotto A, Bosio C, Mangar D, Chen C, Cannato M, Toniolo L, Garetto G, Nasole E, Bassi C. Effect of hyperbaric oxygenation and gemcitabine on apoptosis of pancreatic ductal tumor cells in vitro. *Anticancer Res* 2013; 33: 4827–4832.

Catalano V, Dentice M, Ambrosio R, Luongo C, Carollo R, Benfante A, Todaro M, Stassi G, Salvatore D. Activated Thyroid Hormone Promotes Differentiation and Chemotherapeutic Sensitization of Colorectal Cancer Stem Cells by Regulating Wnt and BMP4 Signaling. *Cancer Res* 2016; 76: 1237–1244.



Chaiyabutr N and Jakobsen PE. The influence of dietary iodine and environmental temperature on the activity of mitochondria in liver and kidney. *Z Tierphysiol Tierernahr Futtermittelkd* 1978; 40: 225–235.

Cheng ML and Solit DB. Opportunities and Challenges in Genomic Sequencing for Precision Cancer Care. *Ann Intern Med* 2018; 168: 221–222.

Cheng Y, Weng S, Yu L, Zhu N, Yang M, Yuan Y. The Role of Hyperthermia in the Multidisciplinary Treatment of Malignant Tumors. *Integr Cancer Ther* 2019; 18: 1534735419876345.

Dentice M, Marsili A, Zavacki A, Larsen PR, Salvatore D. Version 2. The deiodinases and the control of intracellular thyroid hormone signaling during cellular differentiation. *Biochim Biophys Acta* 2013; 1830: 3937–3945.

Evans SS, Repasky EA, Fisher DT. Fever and the thermal regulation of immunity: the immune system feels the heat. *Nat Rev Immunol* 2015; 15: 335–349.

Furth PA. Cancer prevention as biomodulation: targeting the initiating stimulus and secondary adaptations. *Ann NY Acad Sci* 2012; 1271: 1–9.

Galofré JC, Fernández-Calvet L, Ríos M, García-Mayor RV. Increased incidence of thyrotoxicosis after iodine supplementation in an iodine sufficient area. *J Endocrinol Invest* 1994a; 17: 23–27.

Galofré JC, García-Mayor RV, Fluiters E, Fernández-Calvet L, Rego A, Pàramo C, Andrade MA. Incidence of different forms of thyroid dysfunction and its degrees in an iodine sufficient area. *Thyroidology* 1994b; 6: 49–54.

Gulaboglu M, Yildiz L, Celebi F, Gul M, Peker K. Comparison of iodine contents in gastric cancer and surrounding normal tissues. *Clin Chem Lab Med* 2005; 43: 581–584.

Hays MT and Solomon DH. Influence of the gastrointestinal iodide cycle on the early distribution of radioactive iodide in man. *J Clin Invest* 1965; 44: 117.

Hegde PS and Chen DS. Top 10 Challenges in Cancer Immunotherapy. *Immunity* 2020; 52: 17–35.

Heimbuch BK, Harnish DA, Balzli C, Lumley A, Kinney K, Wander JD. Aerosol-phase activity of iodine captured from a triiodide resin filter on fine particles containing an infectious virus. *J Appl Microbiol* 2015; 118: 1315–1320.

Iwata A, Morrison ML, Roth MB. Iodide Protects Heart Tissue from Reperfusion Injury. *PLoS One* 2014; 9: e112458.

Kaushal N, Gupta Y, Goyal M, Khaiboullina SF, Baranwal M, Verma SC. Mutational Frequencies of SARS-CoV-2 Genome during the Beginning Months of the Outbreak in USA. *Pathogens* 2020; 9: 565.

Klotz KH and Benz R. Kinetics of the iodine- and bromine-mediated transport of halide ions: demonstration of an interfacial complexation mechanism. *Biophys J* 1993; 65: 2661–2672.

Kogai T, Schultz JJ, Johnson LS, Huang M, Brent GA. Retinoic acid induces sodium/iodide symporter gene expression and radioiodide uptake in the MCF-7 breast cancer cell line. *Proc Natl Acad Sci USA* 2000; 97: 8519–8524.

Lee YS, Chin YT, Shih YJ, Shih YJ, Nana AW, Chen YR, Wu HC, S H Yang YC, Lin HY, Davis PJ. Thyroid Hormone Promotes  $\beta$ -Catenin Activation and Cell Proliferation in Colorectal Cancer. *Horm Cancer* 2018; 9: 156–165.

Leung AM and Braverman LE. Consequences of excess iodine. *Nat Rev Endocrinol* 2014; 10: 136–142.

Lin Q, Li S, Jiang N, Shao X, Zhang M, Jin H, Zhang Z, Shen J, Zhou Y, Zhou W, Gu L, Lu R, Ni Z. PINK1-parkin pathway of mitophagy protects against contrast-induced acute kidney injury via decreasing mitochondrial ROS and NLRP3 inflammasome activation. *Redox Biol* 2019; 26: 101254.

Locy H, de Mey S, de Mey W, De Ridder M, Thielemans K, Maenhout SK. Immunomodulation of the Tumor Microenvironment: Turn Foe Into Friend. *Front Immunol* 2018; 9: 2909.

Mahmood J, Shukla HD, Soman S, Samanta S, Singh P, Kamlapurkar S, Saeed A, Amin NP, Vujaskovic Z. Immunotherapy, Radiotherapy, and Hyperthermia: A Combined Therapeutic Approach in Pancreatic Cancer Treatment. *Cancers (Basel)* 2018; 10: 469.

Miura N, Ishihara Y, Miura Y, Kimoto M, Miura K. miR-520d-5p can reduce the mutations in hepatoma cancer cells and iPSCs-derivatives. *BMC Cancer* 2019; 19: 587.

Moen I and Stuhr LE. Hyperbaric oxygen therapy and cancer--a review. *Target Oncol* 2012; 7: 233–242.

Moreno-Vega A, Vega-Riveroll L, Ayala T, Peralta G, Torres-Martel JM, Rojas J, Mondragón P, Domínguez A, Obaldía RD, Avelilla-Guerrero C, Anguiano B, Delgado-González E, Zambrano-Estrada X, Cuenca-Micó O, Flores OD, Varela-Echavarría A, Aceves C. Adjuvant Effect of Molecular Iodine in Conventional Chemotherapy for Breast Cancer. Randomized Pilot Study. *Nutrients* 2019; 11: 1623.

Multhoff G, Hahl G, Combs SE. Rationale of hyperthermia for radio(chemo)therapy and immune responses in patients with bladder cancer: Biological concepts, clinical data, interdisciplinary treatment decisions and biological tumour imaging. *Int J Hyperthermia* 2016; 32: 455–463.

Nava-Villalba M, Nuñez-Anita RE, Bontempo A, Aceves C. Activation of Peroxisome Proliferator-Activated Receptor Gamma Is Crucial for Antitumoral Effects of 6-iodolactone. *Mol Cancer* 2015; 14: 168.

Nicola JP, Basquin C, Portulano C, Reyna-Neyra A, Paroder M, Carrasco N. The Na<sup>+</sup>/I<sup>-</sup> Symporter Mediates Active Iodide Uptake in the Intestine. *Am J Physiol Cell Physiol* 2009; 296: C654–662.

Ohguri T, Imada H, Narisada H, Yahara K, Morioka T, Nakano K, Miyaguni Y, Korogi Y. Systemic chemotherapy using paclitaxel and carboplatin plus regional hyperthermia and hyperbaric oxygen treatment for non-small cell lung cancer with multiple pulmonary metastases: preliminary results. *Int J Hyperthermia* 2009; 25: 160–167.

Okamoto H, Nozaki M, Kanamoto H, Gomi M, Yano H. Inactivating Effects and Cytotoxicity of Oropharyngeal Medicines on Pharyngeal Infection Viruses. *J Antibacterial and Antifungal Agents* 2018; 46: 143–148.

Rosenholm JB, Peiponen KE, Gornov E. Materials Cohesion and Interaction Forces. *Adv Colloid Interface Sci* 2008; 141: 48–65.

Schubert J and Chanana M. Coating Matters: Review on Colloidal Stability of Nanoparticles with Biocompatible Coatings in Biological Media, Living Cells and Organisms. *Curr Med Chem* 2019; 25: 4556–4586.

Shelanski HA and Shelanski MV. PVP-iodine: history, toxicity, and therapeutic uses. *J Int Coll Surg* 1956; 25: 727–734.

Shimizu K, Iyoda T, Okada M, Yamasaki S, Fujii SI. Immune suppression and reversal of the suppressive tumor microenvironment. *Int Immunol* 2018; 30: 445–454.

Shimoda M, Mellody KT, Orimo A. Carcinoma-associated fibroblasts are a rate-limiting determinant for tumor progression. *Semin Cell Dev Biol* 2010; 21: 19–25.

Spitzweg C, Heufelder AE, Morris JC. Thyroid iodine transport. *Thyroid* 2000; 10: 321–330.

Stępień K, Ostrowski RP, Matyja E. Hyperbaric oxygen as an adjunctive therapy in treatment of malignancies, including brain tumours. *Med Oncol* 2016; 33: 101.

Supawat B, Udomtanakunchai C, Kothan S, Tungjai M. The Effects of Iodinated Radiographic Contrast Media on Multidrug-resistant K562/Dox Cells: Mitochondria Impairment and P-glycoprotein Inhibition. *Cell Biochem Biophys* 2019; 77: 157–163.

Venturi S, Venturi A, Cimini D, Arduini C, Venturi M, Guidi A. A new hypothesis: iodine and gastric cancer. *Eur J Cancer Prev* 1993; 2: 17–23.

Verheesen RH and Schweitzer CM. Iodine deficiency, more than cretinism and goiter. *Med Hypotheses* 2008; 71: 645–648.

Watanabe M. The Main Target of Carcinogenesis Is Not DNA. *Gan To Kagaku Ryoho* 2015; 42: 2409–2413.

Weir HK, Thompson TD, Soman A, Møller B, Leadbetter S. The past, present, and future of cancer incidence in the United States: 1975 through 2020. *Cancer* 2015; 12: 1827–1837.

Yokoyama M. Up-to-date Chemistry & Technological Application for Iodine (Popular Edition). *CMC publishing* 2018.

Yu G, Tzouveleakis A, Wang R, Herazo-Maya JD, Ibarra GH, Srivastava A, de Castro JPW, DeLuliis G, Ahangari F, Woolard T, Aurelien N, Arrojo E, Drigo R, Gan Y, Graham M, Liu X, Homer RJ, Scanlan TS, Mannam P, Lee PJ, Herzog EL, Bianco AC, Kaminski N. Thyroid hormone inhibits lung fibrosis in mice by improving epithelial mitochondrial function. *Nat Med* 2018; 24: 39–49.

Zhou H, Randers-Pehrson G, Waldren CA, Vannais D, Hall EJ, Hei TK. Induction of a bystander mutagenic effect of alpha particles in mammalian cells. *Proc Natl Acad Sci USA* 2000; 97: 2099–2104.